

COLLEMBOLA (SPRINGTAILS) (ARTHROPODA: HEXAPODA: ENTOGNATHA) FOUND IN SCRAPINGS FROM INDIVIDUALS DIAGNOSED WITH DELUSORY PARASITOSIS

DEBORAH Z. ALTSCHULER,¹ MICHAEL CRUTCHER, MD, MPH, FACPM,²
NECULAI DULCEANU, DVM, PhD (DECEASED),³ BETH A. CERVANTES,¹
CRISTINA TERINTE, MD, PhD⁴ AND LOUIS N. SORKIN, BCE⁵

¹National Pediculosis Association, 50 Kearney Road, Needham, Massachusetts 02494;

²Commissioner of Health, Oklahoma State Department of Health,
1000 NE 10th Street, Oklahoma City, Oklahoma 73117;

³Department of Parasitology, University of Veterinary Medicine, Iasi, Romania;

⁴Department of Pathology, University of Medicine and Pharmacy, Iasi, Romania; and

⁵Division of Invertebrate Zoology, American Museum of Natural History,
Central Park West at 79th Street, New York, New York 10024-5192

Abstract.—Twenty individuals diagnosed with delusory parasitosis participated in a single site clinical study under the auspices of the National Pediculosis Association (NPA) and the Oklahoma State Department of Health. The objective of this study was to determine if there were any common factors in skin scrapings collected from this population. These individuals, whose symptoms were originally attributed to lice or scabies, were part of a larger group reporting symptoms of stinging/biting and/or crawling to the NPA. Multiple skin scrapings from each person were microscopically examined. Any and all fields of view that appeared incongruous to normal human skin were digitally photographed. When the photographic images were initially evaluated, no common factor was identified. However, more extensive scrutiny using imaging software revealed evidence of Collembola in 18 of the 20 participants.

Key words: Collembola, springtail, stinging, biting, crawling, Arthropoda, Hexapoda, Entognatha, pediculosis, human skin, lice and scabies.

Delusory parasitosis, also known as Ekbom's Syndrome (Ekbom, 1938), is a presumed psychiatric condition ascribed to individuals who are convinced, in the absence of any empirical evidence, that they are infested with an insect or parasite (Novak, 1988; Poorbaugh, 1993; Webb, 1993a). These individuals experience itching, stinging/biting, and crawling sensations on or under their skin, which are often associated with excoriations, discoloration, scaling, tunneling or sores. Their conviction that they are infested is reinforced by their observation of particles described as sparkly, crusty, crystal-like, white or black specks and/or fibers. Typically, these individuals have consulted extensively with general physicians, dermatologists, and entomologists (Kushon et al., 1993) who could not find physical cause for their complaints. Despite findings ruling out lice, scabies or other medical causes, patients refuse to accept the diagnosis of delusory parasitosis (Koblenzer, 1993; Webb, 1993b), become extremely focused on eradicating the pests, and further compromise their skin by frequent scratching, excessive cleaning, and the application of various remedies such as prescription pesticides for lice or scabies, household cleaning products, and organic solvents or fuels. The symptoms are debilitating and the sufferer's distress is compounded by the lack of a concrete physical diagnosis.

Hundreds of sufferers have reported symptoms to the National Pediculosis Association (NPA), as well as to the Oklahoma State Department of Health, similar to those described by Traver in reporting her own infestation (Traver, 1951). In response to the compelling nature of these reports, the NPA agreed to conduct a controlled research study of skin specimens in cooperation with the Oklahoma State Health Department. Twenty individuals diagnosed as having delusory parasitosis and ten non-symptomatic controls volunteered to participate in this effort. The clinical portion of the study was conducted at a single site during three weeks. Doctors with experience in the skin scraping method of specimen collection obtained and microscopically examined samples, and all anomalous findings were photographed. Procedures were instituted to preclude contamination, such as reported by Poorbaugh (1993).

STUDY DESIGN

Study Locale. The clinical portion of this study was conducted at the Oklahoma State Department of Health, Oklahoma City, Oklahoma between June 28 and July 20, 2000.

Study Participants. Twenty symptomatic participants were selected from the hundreds of individuals who had previously contacted the NPA regarding an unknown condition possibly associated with lice and/or scabies but for which these parasites had been ruled out. Their physicians subsequently diagnosed them as suffering from delusory parasitosis. These volunteers were accepted on the basis of their willingness to travel to Oklahoma City at their own expense, complete questionnaires regarding their symptoms and medical history, and submit to multiple skin scrapings. Ten controls, randomly selected from employees of the Oklahoma State Health Department, were also enrolled. All participants signed a waiver of liability and understood that this was an initial research effort.

Intake Evaluations. Intake consisted of having symptomatic participants complete a self-administered questionnaire that was similar in content to the "not-lice" survey posted on the NPA website (www.headlice.org). Body diagrams of ventral and dorsal surfaces were marked to identify common areas of lesions. Two participants had symptoms without lesions or dermatitis at the time of the trial.

Specimen Preparation. Trained personnel prepared all skin scrapings. Prior and subsequent to scraping the skin with a disposable scalpel, symptomatic areas and areas at or around lesions were cleansed with gauze and alcohol. Immediately after being obtained, the scraped material was transferred to a fresh microscope slide with a drop of sterile water, coverslipped and isolated. Between 15 and 35 slides were prepared and examined for each subject. Scrapings were obtained from non-symptomatic controls from regions of the body where most lesions were noted on symptomatic participants.

Specimen Photography and Data Tracking. All slides were viewed using an Olympus BX60 Dual Viewing Microscope. The images that appeared incongruent with normal healthy skin were photographed using a SPOT RGB digital camera and SPOT software version 3.0. Each image was assigned a unique identifier and the magnification of the image was recorded. Images were sized by comparison with images of a B&L micrometer with marks for 0.1 mm and 0.01 mm that were taken at 100 \times , 200 \times and 400 \times magnification with the same camera and software used in the clinical study. Initial microscopy was non-blinded; i.e., the clinicians examining and photographing the slides knew that they were from either the study participant or control group.

RESULTS

Over 300 microscopic fields from study participants who complained of stinging/biting and/or crawling sensations in their skin appeared incongruent with normal skin and therefore were photographed for later scrutiny.

Pollen, conidia or spores, hyphae, mycelium or fibers, or what appeared to be clumped skin or cellular debris were identified during the first six months of image analysis. One or two-cell algae, nematodes, or what appeared to be insect eggs, larvae or embryos were also identified. Although everyone in the group had at least one of the above findings, none of the findings were a common factor in every subject, making it necessary to continue looking for a common denominator. Because Collembola had been reported from individuals experiencing these symptoms (Dasgupta and Dasgupta, 1995; Frye, 1997; Scott et al., 1962), they became the focus of subsequent image analysis.

Identification of Collembola in scrapings from symptomatic study participants required intensive scrutiny of the photographs and was initially very difficult. Most Collembola were enmeshed in accumulations of exuviae. Eggs ranged from 20 to 100 microns in diameter. The size of most Collembola noted was 50–300 microns in length, suggesting a predominance of nymphs as opposed to adults. To ensure reliability of results, researchers verified at least two sightings before a subject was considered to have positive Collembola findings. However, scrapings from 10 of the subjects showed an abundance of Collembola. Evidence of Collembola was found in images of scrapings from 18 of the 20 individuals that had been diagnosed as delusional. Of the two participants without lesions or dermatitis at the time of the trial, one had images positive for Collembola.

Examples of some of these findings and the photographic fields in which they appeared are provided in Fig. 1–3. Each image was obtained from a different study participant.

Fig. 1: Photomicrograph of debris that demonstrated at higher magnification the presence of Collembola. Two examples are highlighted and enlarged in Fig. 1a.

Fig. 2: A clearly recognizable Collembola (approximately 100 microns in length) is resting on top of the debris in the lower right.

Fig. 3: Provides an example of Collembola enmeshed in debris.

Collembola were present in ninety percent of the study participants who complained of stinging/biting and/or crawling sensations on or under their skin.

Microscopic examination of scrapings of control subjects appeared to be consistent with normal skin and therefore no photographic images were taken.

More than 1,500 individuals registered with the NPA (data on file) as having stinging/biting and/or crawling sensations that they initially attributed to lice and/or scabies. Approximately half of these individuals described three or more abnormalities in skin appearance and observed two or more different types of skin particles. The demographics and symptoms of these individuals and the study participants were compared (see Table 1).

DISCUSSION

The findings of Collembola in images of scrapings from 18 of the 20 symptomatic study participants supports their contention that they actually have something crawling on or under their skin and are not delusional. The images were reviewed by entomologists and the presence of Collembola verified and identified as representative of the families Isotomidae and Entomobryidae.

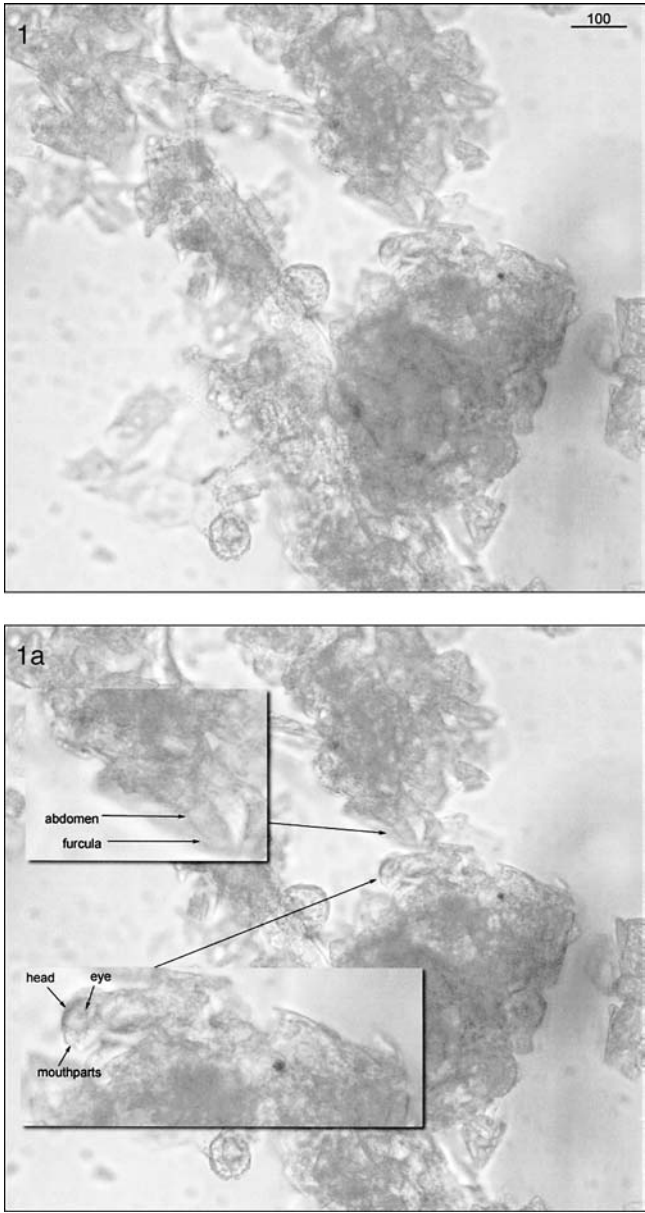


Fig. 1. Debris that demonstrated at higher magnification the presence of Collembola.

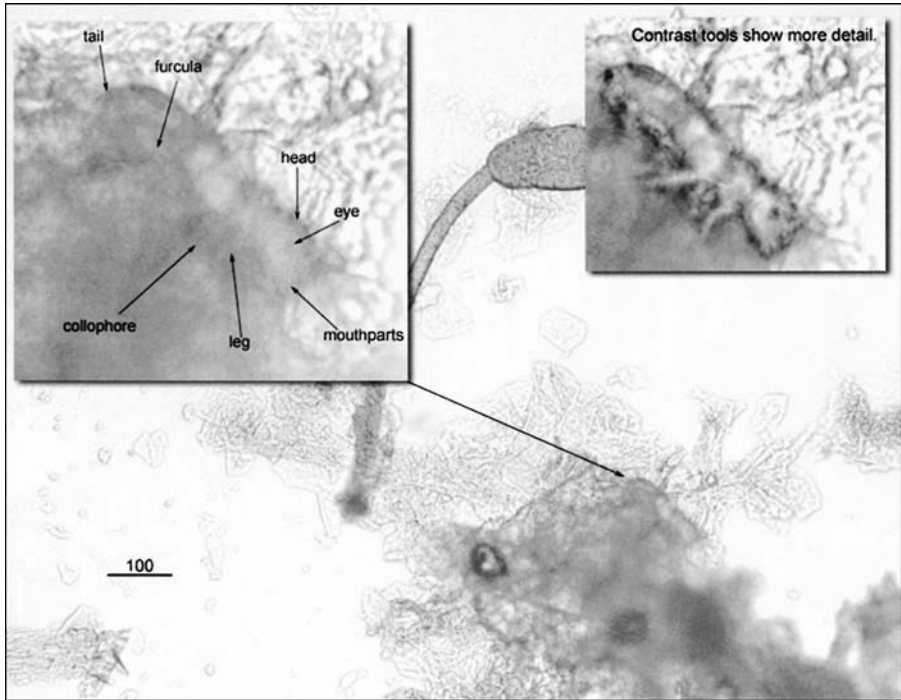


Fig. 2. Collembola in debris in lower right.

The study was designed to minimize any possibility of sample contamination in the skin scrapings. All scrapings were done at a single site by clinicians skilled in the skin scraping method of collection. Microscopic evaluation of skin scrapings from the ten non-symptomatic controls showed nothing incongruous with normal skin and were therefore not photographed. This supports the contention that the methodology employed adequately protected against sample contamination during collection.

A “classic” report of arthropod infestation was reported by Traver (1951) in which the author described an infestation by a mite species on her person. Traver (1951) has been referenced by various authors who gave validity to her infestation. Subsequently, papers were presented during the Symposium: Delusions of Parasitosis, 18 November 1991 refuting her findings and attributing them to equipment contamination. The mite was identified by Fain (1967) as the common house dust mite *Dermatophagoides pteronyssus*.

The directive to photograph all images associated with abnormal skin was critical to identifying Collembola in the skin scrapings. The fields contained fungal mycelium, or what appeared at first glance to be cellular clumps or debris. The Collembola were extremely well hidden in the exuviae and therefore easy to miss. It was only after intense scrutiny that they were recognized. In addition, because the Collembola were not always intact or completely in focus, they were difficult to discern. Given these challenges, it is easy to appreciate why there have been only a few previous reports of Collembola in human skin.

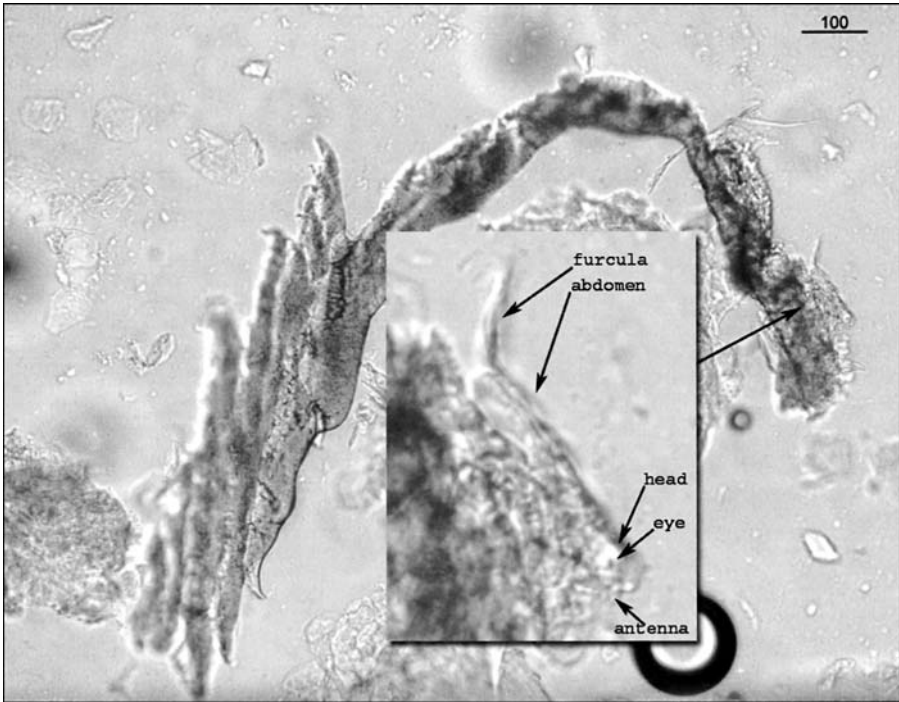


Fig. 3. Collembola enmeshed in debris.

Collembola were identified in skin scrapings submitted to the Entomology Branch of the National Center for Infectious Diseases in 1995 (pers. comm.) by an oncology nurse diagnosed as having delusory parasitosis. Subsequently, there have been additional reports that provided evidence of Collembola in skin from one or more individuals diagnosed with similar symptoms (Dasgupta and Dasgupta, 1995; Frye, 1997). Because the samples were self-collected and contained a number of other anomalies, including fungi spores and filaments, foreign fibers, plus an assortment of "organisms," the finding of Collembola was regarded as intentional or unintentional sample contamination.

In the current study, in which pains were taken to avoid sample contamination, there were over 300 anomalous findings in skin scrapings from the 20 symptomatic study participants and none from controls. These findings included pollen, conidia or spores, hyphae, mycelium, algae or fibers, clumped skin or cellular debris, an occasional nematode, and what appeared to be insect eggs, larvae or embryos. These collective anomalies point to the compromised skin of most of the symptomatic study participants, and could directly or indirectly (through an immune or allergic response) produce sensations of stinging/biting and/or crawling, as well as some of the other symptoms.

Collembola are abundant in wastewater and contaminated environments making them of growing ecotoxicologic importance (Hopkin, 1997). Generally, they feed on decaying matter,

Table 1. Reporting Registry Data

	Symptomatic Study Participants n = 20		Larger Symptomatic Population n = 1681	
	QTY	%	QTY	%
Background				
Sex				
male	3	15%	491	29%
female	17	85%	1,190	71%
Age				
66 or over	2	10%	42	2%
between 41 and 65	11	55%	394	23%
between 26 and 40	7	35%	804	48%
25 or under	0	0%	391	23%
unknown	0	0%	50	3%
General health before onset of symptoms				
excellent	9	45%	751	45%
very good	2	10%	510	30%
good	8	40%	300	18%
fair	1	5%	90	5%
poor	0	0%	30	2%
Others with condition				
in household	10	50%	715	43%
outside household	10	50%	562	33%
Treatment attempts				
over the counter	20	100%	526	31%
prescription	18	90%	484	29%
home-remedy	16	80%	296	18%
Specific abnormalities				
lumps on head, scalp	16	80%	720	43%
hair breaking off	13	65%	458	27%
eyes watery, itchy	13	65%	559	33%
genital symptoms	12	60%	632	38%
Description of symptoms				
Skin sensation				
crawling	18	90%	1,393	83%
stinging/biting	20	100%	1,327	79%
itching	16	80%	1,574	94%
Skin findings				
crystals	17	85%	511	30%
sparkly particles	15	75%	423	25%
crusty particles	15	75%	529	31%
sticky particles	10	50%	314	19%
white specks	15	75%	602	36%
black specks	18	90%	600	36%
fibers	18	90%	485	29%
hair, dust	16	80%	441	26%
one or more of above	20	100%	1,116	66%

Table 1. Continued.

	Symptomatic Study Participants n = 20		Larger Symptomatic Population n = 1681	
	QTY	%	QTY	%
two or more of above	20	100%	802	48%
three or more of above	19	95%	604	36%
Skin appearance				
sores	18	90%	990	59%
rash	12	60%	856	51%
scaling	16	80%	639	38%
discoloration	15	75%	541	32%
scarring	16	80%	668	40%
tracks	16	80%	585	35%
one or more of above	19	95%	1,398	83%
two or more of above	19	95%	1,084	64%
three or more of above	19	95%	772	46%

algae, fungi and bacteria. In fact, a fungal infection appears to be a prerequisite condition before collembolans can gain access into the abdominal cavities of cabbage maggot flies *Delia radicum* (Griffiths, 1985). Some species of Collembola are known plant and mushroom pests and one species has been taken from dried milk powder (Scott, 1996).

Typical collembolan habitats are moist environments with high humidity and abundant organic debris. These conditions are present in the lesions in symptomatic study participants; it is possible Collembola found in lesions are opportunistic and that fungal infections or allergic reactions to pollen, fungi, spores or other organisms may contribute to or be responsible for the symptoms these individuals experience. Collembola do not need to be human parasites in order to be present in the skin scrapings.

Photographs were taken of all scrapings showing anything inconsistent with normal skin. After identifying these anomalies as pollen, spores, etc., more extensive scrutiny revealed the presence of Collembola. Since it was the pollen, spores, hyphae, fiber and other microorganisms that prompted the photography, it is not known if Collembola (without any pollen, spores, etc.) could have been present in the control group.

The population studied in this trial was a subset of over 1,500 individuals registered with the NPA as experiencing crawling and/or biting/stinging sensations in the absence of lice or scabies. This general population shares many of the characteristics of those who participated in the study. Although the questionnaire utilized was self-administered and had its limitations, it is reasonable to postulate that a percentage of this more general population may very well have similar findings to the 20 symptomatic individuals who participated in this study.

More research is required before the true prevalence and importance of Collembola in humans can be ascertained.

ACKNOWLEDGMENTS

The authors would like to acknowledge Ferris J. Barger for his help with microphotography and Dr. BethAnn Friedman and Jane Cotter for manuscript preparation.

LITERATURE CITED

- Dasgupta, R. and B. Dasgupta. 1995. A treatise on zoophily in Collembola with a summary of knowledge on origin and evolution of parasitism in saprophagous forms of animals. *Journal of Bengal Natural History Society* 14: 53–60.
- Ekbohm, K. A. 1938. Der prasenile Dermatozoenwahn. *Aus. Derm. Krankenhause Beckomberga, Angby (Stockholm) Vorstrand: Chefarzt Dr. 7. Wiesel*, pp. 227–259.
- Fain, A. 1967. Le genre *Dermatophagoides* Bogdanow 1864. Son importance dans les allergies respiratoires et cutanées chez l'homme (Psoroptidae: Sarcoptiformes). *Acarologia* 9: 179–225.
- Frye, F. L. 1997. In search for the haphazardly elusive: a follow-up report on an investigation into the possible role of Collembolans in human dermatitis. *Veterinary Invertebrate Society Newsletter* 13: 12.
- Griffiths, G. C. D. 1985. *Hypogastrua succinea* (Collembola: Hypogastruridae) dispersed by adults of the cabbage maggot, *Delia radicum* (Diptera: Anthomyiidae), infected with the parasitic fungus, *Strongewellsea castrans* (Zygomycetes: Entomophtoraceae). *Canadian Entomologist* 117(8): 1063–1064.
- Hopkin, S. P. 1997. *Biology of the Springtails (Insecta: Collembola)*. Oxford University Press, New York. 48. x + 330 pp.
- Koblentz, C. S. 1993. The clinical presentation. Diagnosis and treatment of delusions of parasitosis—a dermatologic perspective. *Bulletin of the Society for Vector Ecology* 18(1): 6–10.
- Kushon, D. J., J. W. Helz, J. M. Williams, K. M. K. Lau, L. L. Pinto and F. E. St. Aubin. 1993. Delusions of parasitosis: a survey of entomologists from a psychiatric perspective. *Bulletin of the Society for Vector Ecology* 18(1): 11–15.
- Novak, M. 1988. Psychocutaneous medicine: delusions of parasitosis. *Cutis* 42(6): 504.
- Poorbaugh, J. H. 1993. Cryptic arthropod infestations: separating fact from fiction. *Bulletin of the Society for Vector Ecology* 18(1): 3–5.
- Scott, H. G. 1966. Insect pests. Part 1. Springtails. *Modern Maintenance Management* 18(9): 19–21.
- Scott, H. G., J. S. Wiseman and C. J. Stojanovich. 1962. Collembola infesting man. *Annals of the Entomological Society of America* 55(4): 428–430.
- Traver, J. 1951. Unusual scalp dermatitis in humans caused by the mite *Dermatophagoides* (Acarina, Epidermoptidae). *Proceedings of the Entomological Society of Washington* 53(1): 1–25.
- Webb, J. P. 1993a. Delusions of parasitosis: a symposium: coordination among entomologists, dermatologists and psychiatrists. *Bulletin of the Society for Vector Ecology* 18(1): 1–2.
- Webb, J. P. 1993b. Case histories of individuals with delusions of parasitosis in southern California and a proposed protocol for initiating effective medical assistance. *Bulletin of the Society for Vector Ecology* 18(1): 16–25.

Received 18 August 2003; accepted 15 February 2004.